

## RISK OF HAEMORRHAGIC COMPLICATIONS OF RETROPUBIC SURGERY IN FEMALES: ANATOMIC REMARKS

Ladislav Jaburek<sup>a</sup>, Jana Jaburkova<sup>b</sup>, Marek Lubusky<sup>a</sup>, Martin Prochazka<sup>a\*</sup>

<sup>a</sup> Department of Obstetrics and Gynaecology, University Hospital Olomouc, Czech Republic

<sup>b</sup> Department of Anatomy, Faculty of Medicine and Dentistry, Palacky University Olomouc  
E-mail: martin.prochazka@fnol.cz

Received: September 28, 2010; Accepted with revision: January 1, 2011

Key words: Urogynaecology/Retropubic surgery/Bleeding/Corona mortis/TVT

**Background.** An anatomic study.

**Objective.** To point out the risk of bleeding during retropubic surgery in females.

**Methods.** A pelvic dissection, preparation of vessels and photodocumentation in colour.

**Results.** A detailed representation of topographic vessel relations in pelvic and retropubic regions is presented. This could be used as an authentic visual aid for postgraduate training in urogynaecological surgery.

**Conclusion.** This study highlights the risk of vascular lesions common to all suspensory surgical procedures for female stress urinary incontinence. Apart from paraurethral vessels, the vessels of the urinary bladder, the paravesical plexuses, the retropubic anastomosis and the external iliac vessels can be injured in surgery. Preceded by training at an accredited urogynaecologic centre, TVT can be considered a safe method. Introduction of other modifications such as the transobturator system (namely the + “inside-out” method) makes all urogynaecological surgical procedures much safer.

### INTRODUCTION

Retropubic surgical procedures in females such as the TVT (Tension-free Vaginal Tape) in their modifications is a needle suspension retropubic operation for stress urinary incontinence. The technique was introduced by Ulmsten et al.<sup>1</sup> in 1996. As a one-day surgery performed in local or regional anaesthesia it has some advantages over the Burch colposuspension. The operation requires only minimal excisions and tissue dissection and consists in a loose application of a prolene tape, without any fixation, under the middle part of the urethra. In this way the tape creates a support, exerting neither traction nor tension. The operation results in complete elimination or a significant improvement of incontinence in about 90% of patients. At present, this method is widely used all over the world. Operations are performed with a minimum of complications and long-lasting good results<sup>2,3</sup>. Nevertheless, there is some risk of vascular injury during the needle penetration in the retropubic part of the procedure which cannot be done under visual control. Not only paraurethral vessels but also the vessels of the urinary bladder, the paravesical plexuses, the retropubic anastomosis and the external iliac vessels may be injured.

### SUBJECT MATTER

#### *Paraurethral vessels*

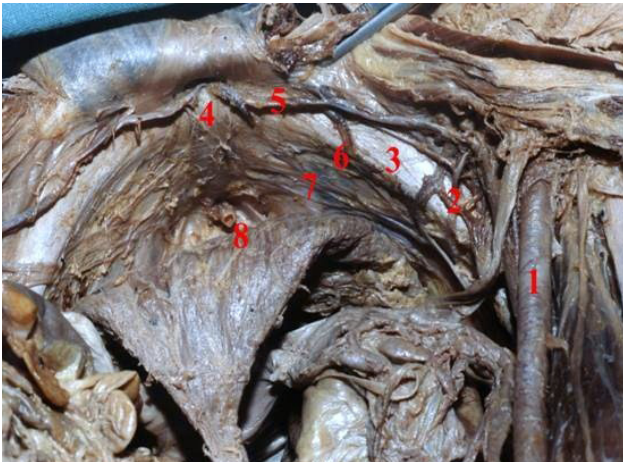
The blood supply to the urethra is provided by the branches of the cervicovaginal artery (from the uterine artery) and the branches of the inferior vesical artery (from the internal iliac artery). In the perineal part, the

urethra is supplied by the branches of the artery of the bulb of the vestibule (from the internal pudendal artery). The venous blood is drained into interconnected plexuses, the vesicovaginal plexus situated paraurethrally and the pudendal plexus Santorini which lies under the symphysis. Bleeding can be prevented by a minimal paraurethral dissection just sufficient to create an initial channel for the needle insertion. With preparation scissors it is then possible to gently perforate the urogenital diaphragm. If there is no contraindication for anaesthesia, a local anaesthetic with a vasoconstrictory additive (Supracaine 4%) can be infiltrated paraurethrally (a hydrodissection).

#### *Urinary bladder vessels and paravesical plexuses*

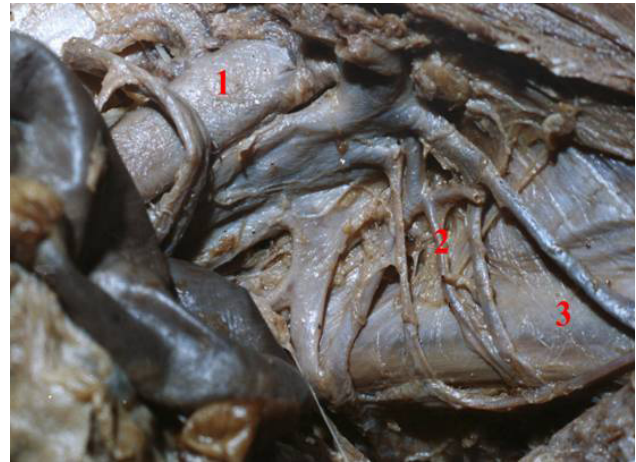
The arteries for the urinary bladder come in pairs from both sides. These are: the superior vesical artery (from the umbilical artery) and the inferior vesical artery (from the internal iliac artery). Tiny branches for the urinary bladder, the anterior vesical arteries, divert from the internal pudendal artery and the obturator artery. Other small branches, the posterior vesical arteries, divert from the medial rectal artery. Venous blood from the urinary bladder is collected from three regions – the venous submucosal plexus, the muscular plexus and the perivesical plexus, which have mutual anastomoses. They lead into the interconnected plexuses in the tenuous tissues of the cavum Retzii. It is the vesicovaginal plexus, from which the vesical veins lead into the internal iliac veins and the pudendal plexus Santorini, which drains blood into the internal pudendal vein. The important vessel stems are situated paravesically.

The risk of bleeding can be markedly decreased if contact of the introduced needle with the posterior wall



**Fig. 1.** Contralateral retropubic anastomoses and the corona mortis on the right side.

- 1 right external iliac artery
- 2 right corona mortis
- 3 right pubic bone
- 4 pubic symphysis
- 5 interepigastric anastomosis
- 6 interobturator anastomosis
- 7 interpubdental anastomosis
- 8 female urethra



**Fig. 2.** Corona mortis on the left side.

- 1 left external iliac artery
- 2 left corona mortis
- 3 left pubic bone

tomoses only develop in 50%, the arterial ones in 14%, and anastomoses of both kinds develop in the rest. The average distance of the medial border of the anastomosing ceou,

of the pubic bone is maintained. The flexion in the hip joints should not be greater than 60° so that with the manipulation with the rigid catheter guide the bladder neck can be easily moved in the opposite direction. Moderate flexion of hip joints also contributes to lesser congestion of pelvic vessels.

#### *Retropubic anastomoses*

The retropubic anastomoses pass along the posterior wall of the pubic bone and function as a part of the supplementary collateral pelvic circulation in some types of aortoiliac obstructions. There are contra- and the homolateral anastomoses.

The **contralateral anastomoses** are formed by transversal junctions on three levels (Fig. 1) right next to the upper margin of the pubic bone the anastomoses are formed by the inferior epigastric vessels, in the middle by the obturator vessels and at the lower margin by the internal pudendal vessels<sup>4</sup>.

The atraumatic construction of the needle tip also helps to minimize the risk of injury to these vessels.

The **homolateral anastomoses**, in contrast, represent an actual risk of vessels lesions during the lateral penetration of needles. Bleeding can occur from the known anastomosis between the obturator artery and the inferior epigastric artery (Fig. 2). This ramus pubicus anastomoticus became sadly famous as the corona mortis

Hesselbachi in the past, when the strangulated inguinal hernia was treated by the percutaneous dissection of the hernial hilum. Bleeding in this situation requires surgical revision of the cavum Retzii. The corona mortis is present in 31% in our population<sup>5</sup>. The venous anas-

paravesical plexuses, the retropubic anastomosis and the external iliac vessels can also be injured. The risk of bleeding can be decreased to a minimum by strict adherence to the guidelines for this surgical procedure suggested by Ulmsten et al.<sup>1</sup> and in all awareness of the anatomic situation in the cavum Retzii. The area of safe needle insertion is not more than 3 cm to both sides from the middle of the symphysis. On condition that the implementation of the procedure is preceded by training at an accredited urogynaecologic centre, TVT can be considered a safe method of surgical treatment which conforms to all the criteria of a one-day procedure. Introduction of other modifications such as the transobturator system (namely the + “inside-out” method) makes all the urogynaecological surgical procedures much safer. A thorough understanding of the vascular anatomy in this space should help avoid serious operative complications<sup>8-10</sup>.

## REFERENCES

1. Ulmsten U, Henriksson L, Johnson P, Varhos G. An ambulatory surgical procedure under local anesthesia for treatment of female urinary incontinence. *Int Urogynecol J* 1996;7:81-86.
2. Ulmsten U, Johnson P, Rezapour M. A three-year follow up of tension free vaginal tape for surgical treatment of female stress urinary incontinence. *Brit J Obstet Gynaecol* 1999;106:345-350.
3. Wang AC, Lo TS. Tension-free Vaginal Tape - A minimally Invasive Solution to Stress Urinary Incontinence in women. *J Reprod Med* 1998;43:429-434.
4. Weigner K. *Topograficka anatomie IV*; 2nd ed. Prague: Vesmir; 1936.
5. Dylevsky I, Ticha J. Variability of the Branches of the Arteria iliaca interna. *Folia Morphol* 1987;35:425-435.
6. Tornetta P 3rd, Hochwald N, Levine R. Corona mortis. Incidence et location. *Clin Orthop* 1996. p. 97-101.
7. Jaburkova J. Collaterals and variations of human female pelvic vessels related to gynaecological surgery. Thesis; Olomouc; 2001.
8. Pathi SD, Castellanos ME, Corton MM. Variability of the retropubic space anatomy in female cadavers. *Am J Obstet Gynecol* 2009;201(5):524.e1-5.
9. Kachlik D, Pechacek V, Musil V, Baca V. The venous system of the pelvis: new nomenclature. *Phlebology* 2010;25(4):162-73.
10. Darmanis S, Lewis A, Mansoor A, Bircher M. Corona mortis: an anatomical study with clinical implications in approaches to the pelvis and acetabulum. *Clin Anat* 2007;20(4):433-9.

